

## Ethambutol-induced optic neuropathy in a patient with pulmonary tuberculosis: The need for early ophthalmic surveillance

Dr. Anjana Venugopal<sup>1</sup>, Dr. Vignesh T M<sup>2</sup>, Dr. Sudhakar N A<sup>3</sup>, Dr. Preethiraj Ballal<sup>4</sup>, Dr. Anirudha K<sup>5</sup>

<sup>1</sup> Junior Resident, Department of Ophthalmology, KVG Medical College and Hospital, Sullia, Karnataka, India

<sup>2</sup> Junior Resident, Department of Respiratory Medicine, KVG Medical College and Hospital, Sullia, Karnataka, India

<sup>3</sup> Professor and Head, Department of Ophthalmology, KVG Medical College and Hospital, Sullia, Karnataka, India

<sup>4</sup> Associate Professor, Department of Respiratory Medicine, KVG Medical College and Hospital, Sullia, Karnataka, India

<sup>5</sup> Assistant Professor, Department of Respiratory Medicine, KVG Medical College and Hospital, Sullia, Karnataka, India

Corresponding Author: Dr. Vignesh T. M

### Abstract

Ethambutol is a first-line antitubercular drug widely used under the National Tuberculosis Elimination Programme (NTEP). Although considered relatively safe at recommended doses, ethambutol-induced optic neuropathy (EON) remains a potentially reversible but vision-threatening adverse effect. We report a 50-year-old female with drug-sensitive pulmonary tuberculosis who developed sudden, painless diminution of vision in the right eye after two months of intensive phase therapy (HRZE regimen). Ophthalmic evaluation revealed reduced visual acuity, color vision defect, central scotoma on visual field analysis, and retinal nerve fibre layer changes suggestive of toxic optic neuropathy. Ethambutol was discontinued immediately and modified antitubercular therapy was initiated in consultation with pulmonology. The patient received systemic corticosteroids with partial visual recovery noted on follow-up. Subsequently, after loss to follow-up, she developed similar involvement in the fellow eye, confirming bilateral ethambutol-induced toxic optic neuropathy. This case underscores the importance of baseline and periodic ophthalmic screening in patients receiving ethambutol, especially in high-burden tuberculosis settings such as India.

**Keywords:** Ethambutol, optic neuropathy, tuberculosis, toxic optic neuropathy, visual field defect

### Introduction

India accounts for approximately one-quarter of the global tuberculosis burden [1]. The National Tuberculosis Elimination Programme (NTEP) recommends Ethambutol as part of first-line therapy for drug-sensitive tuberculosis [2]. Ethambutol-induced optic neuropathy (EON), though rare (incidence 0.7-1.2%), remains a potentially reversible but vision-threatening complication [3, 4]. It is characterized by painless visual loss, dyschromatopsia, central scotoma, and optic disc changes [5]. Risk factors include diabetes, renal insufficiency, and malnutrition [6]. The updated NTEP guidelines (2016) extended ethambutol duration from 2 to 6 months, potentially increasing toxicity risk [7]. Early recognition and prompt discontinuation are critical for visual recovery. We report a case highlighting the importance of ophthalmic surveillance in TB management.

### Case Report

A 50-year-old female daily wage worker from rural Karnataka presented to the Department of Ophthalmology with sudden, painless diminution of vision in the right eye of four days' duration. She had been diagnosed with sputum-positive pulmonary tuberculosis two months prior, based on:

- **Sputum smear microscopy:** AFB 3+
- **CBNAAT:** Mycobacterium tuberculosis detected, rifampicin resistance not detected
- **Chest radiography:** Left upper zone cavitory consolidation

She was initiated on intensive phase antitubercular therapy (HRZE: Isoniazid 300 mg, Rifampicin 450 mg, Pyrazinamide 1500 mg, Ethambutol 825 mg daily) as per

NTEP guidelines. The ethambutol dose was approximately 16.5 mg/kg/day. She was compliant with treatment, having completed 56 doses of intensive phase and continuing with the continuation phase (HRE regimen).

The patient had type 2 diabetes mellitus for 10 years, managed with oral hypoglycemic agents. She was poorly built and nourished (BMI 16.4 kg/m<sup>2</sup>), with stable vital parameters. These factors—diabetes and malnutrition—are recognized risk factors for ethambutol toxicity [9].

### Ophthalmic Examination

- **Visual Acuity**  
**Right eye:** Counting Fingers at 3 metres  
**Left eye:** Normal at presentation
- Color vision testing revealed dyschromatopsia (red-green defect)
- **Extraocular movements:** Full and painless
- **Pupillary reactions:** Subtle impairment suggestive of optic nerve dysfunction
- **Fundus examination:** Features suggestive of toxic optic neuropathy in right eye
- **Optical Coherence Tomography (OCT):** Retinal nerve fibre layer (RNFL) thinning and macular ganglion cell layer changes
- **Humphrey Visual Field (30-2) analysis:** Central scotoma in right eye

### Diagnosis and Differential Diagnosis

Based on clinical findings, drug history, and temporal relationship, a diagnosis of ethambutol-induced toxic optic neuropathy was made. Other causes of optic neuropathy were excluded through appropriate investigations:

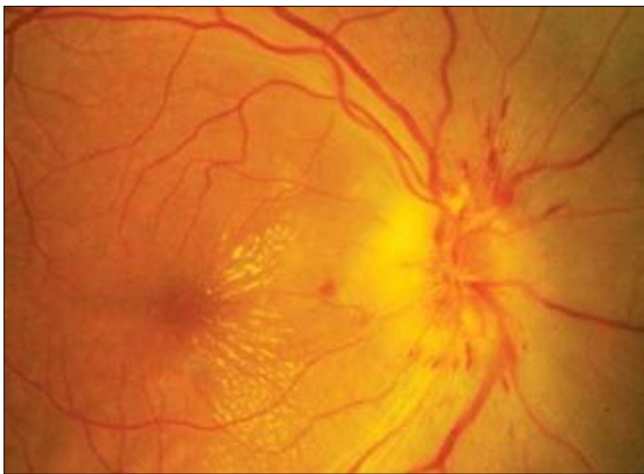- **MRI Brain with Orbit:** No structural abnormalities
- **Toxoplasma screening:** Negative
- **Autoimmune workup:** Within normal limits

**Management**

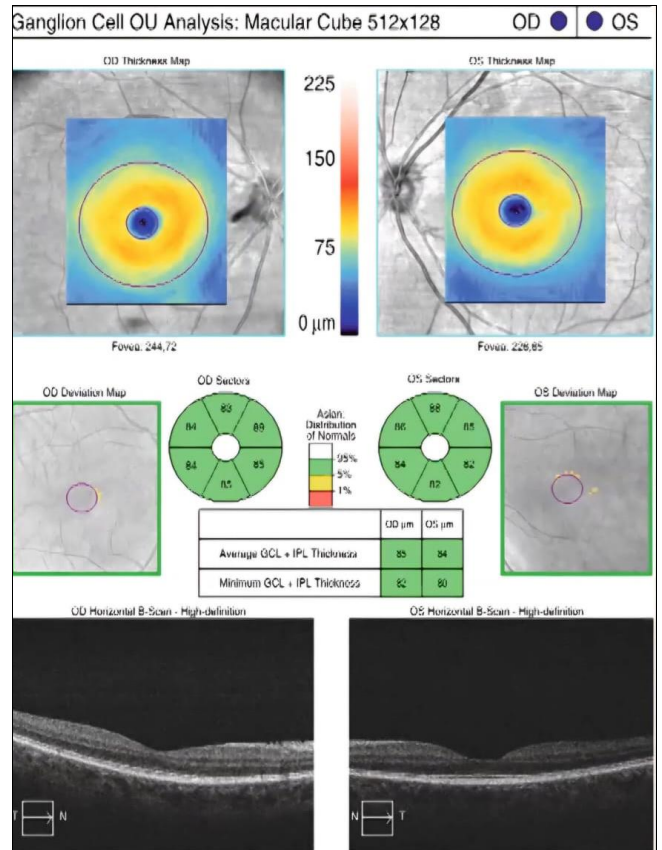
In consultation with the Department of Respiratory Medicine team, the Fixed Drug Combination containing ethambutol was discontinued immediately and modified antitubercular therapy was initiated without ethambutol, substituting with alternative agents as per national guidelines while ensuring effective TB treatment continuation.

The patient was treated with:

- Intravenous methylprednisolone followed by tapering oral prednisolone (following Optic Neuritis Treatment Trial protocol) [10]
- Vitamin B-complex supplementation
- Citicoline for neuroprotection



**Fig 1:** Fundus photograph, right eye



**Fig 3:** OCT Macular Cube, right eye

**Outcome and Follow-up**

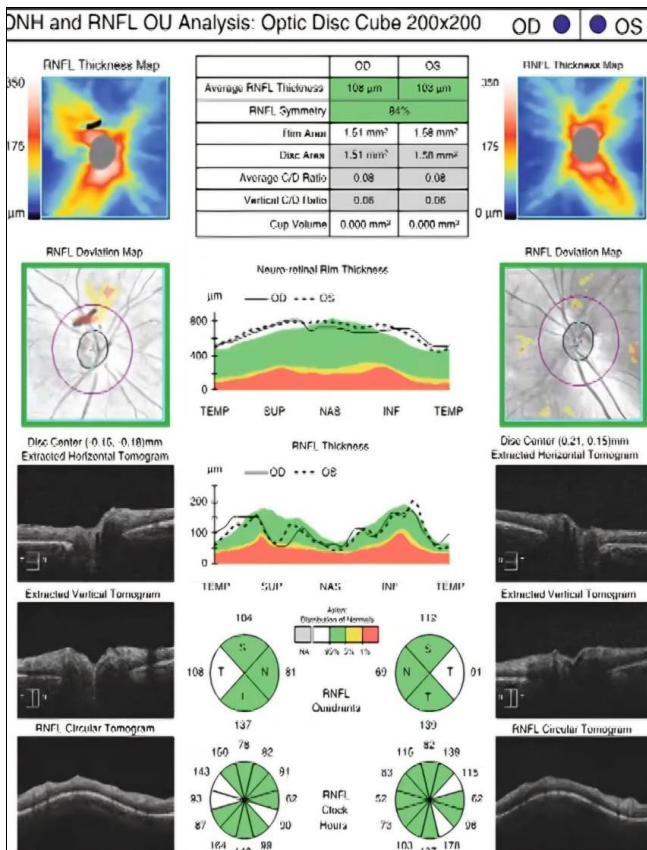
On initial follow-up, right eye visual acuity improved to 6/24 with improvement in color vision, although central scotoma persisted. The patient showed no progression of visual symptoms after ethambutol discontinuation, and respiratory symptoms continued to improve on modified ATT.

However, the patient was lost to follow-up for three months and later presented with similar visual complaints in the left eye. Re-evaluation revealed bilateral involvement consistent with ethambutol-induced toxic optic neuropathy, confirming the diagnosis and emphasizing the importance of continued surveillance even after drug discontinuation.

**Discussion**

Ethambutol chelates zinc and copper, causing mitochondrial dysfunction in retinal ganglion cells, particularly the papillomacular bundle [8, 9]. The metabolite EDDBA accumulates locally, contributing to toxicity [10]. Although no "safe dose" exists, toxicity incidence varies: 18% at 35 mg/kg/day to 1% at 15 mg/kg/day [11]. Our patient received 16.5 mg/kg/day with additional risk factors—diabetes, malnutrition (BMI 16.4 kg/m<sup>2</sup>)—developing toxicity at 2 months, within the typical 2-6 month window [12].

While bilateral involvement is typical, asymmetric or unilateral onset occurs [13, 14]. This case demonstrated initial unilateral involvement progressing to bilateral disease after loss to follow-up. Visual prognosis depends on baseline acuity, early discontinuation, and diagnostic delay. Approximately 60-65% show recovery after drug cessation [15], though outcomes worsen with acuity below 6/60. Our patient's partial recovery emphasizes early intervention importance.



**Fig 2:** OCT ONH and RNFL, right eye

The 2021 expert consensus recommends baseline ophthalmic evaluation, monthly screening for high-risk patients, patient education, and immediate discontinuation upon suspicion [7]. In high TB-burden settings like India, integrating routine screening into NTEP protocols may reduce preventable visual morbidity.

### Conclusion

Ethambutol-induced optic neuropathy is a potentially reversible but serious complication requiring prompt recognition. This case emphasizes the need for baseline and periodic ophthalmic screening, particularly in high-risk patients. Early drug discontinuation and multidisciplinary coordination are crucial for visual recovery. Incorporating standardized surveillance into TB programs may reduce preventable blindness.

### Patient Consent

Written informed consent was obtained from the patient for publication of clinical details.

### Financial Support and Sponsorship

Nil.

### Conflicts of Interest

None.

### References

1. Central Tuberculosis Division, Ministry of Health and Family Welfare, Government of India. India TB Report, 2024. Available from: <https://tbcindia.mohfw.gov.in>
2. Ahirwar G, *et al.* Estimate of TB incidence and critical analysis of programmatic data from Sub-national Certification survey, M.P., India. *J Fam Med Prim Care*, 2025, 14(7).
3. Friedman LN, Dedicoat M, Davies PDO, editors. *Clinical Tuberculosis*. 6th ed. Boca Raton: CRC Press/Taylor & Francis Group, 2020.
4. Korman TM. Ethambutol. In: *Kucers the Use of Antibiotics: A Clinical Review of Antibacterial, Antifungal, Antiparasitic, and Antiviral Drugs*. CRC Press, 2017, 2346-60.
5. Chamberlain PD, Sadaka A, Berry S, Lee AG. Ethambutol optic neuropathy. *Curr Opin Ophthalmol*, 2017;28(6):545-51.
6. Friedman LN, Dedicoat M, Davies PDO, editors. *Clinical Tuberculosis*. 6th ed. Boca Raton: CRC Press/Taylor & Francis Group, 2020.
7. Dahiya M, Rathi M, Dua M, *et al.* Ethambutol-induced optic neuropathy: A re-emerging ocular emergency. *Indian J Clin Exp Ophthalmol*, 2024.
8. Kim J, Ahn SJ. Risk factors of optic neuropathy in ethambutol users. *Toxics*, 2024;12(8):549.
9. Saxena R, Singh D, Phuljhele S, *et al.* Ethambutol toxicity: Expert panel consensus for the primary prevention, diagnosis and management of ethambutol-induced optic neuropathy. *Indian J Ophthalmol*, 2021;69(12):3734-9.
10. Yoon YH, Jung KH, Sadun AA, Shin HC, Koh JY. Ethambutol-induced vacuolar changes and neuronal loss in rat retinal cell culture: mediation by endogenous zinc. *Toxicol Appl Pharmacol*, 2000;162(2):107-14.
11. Kozak SF, Inderlied CB, Hsu HY, Heller KB, Sadun AA. The role of copper on ethambutol's antimicrobial action and implications for ethambutol-induced optic neuropathy. *Diagn Microbiol Infect Dis*, 1998;30(2):83-7.
12. Balhara A, Ladumor MK, Nankar RP, *et al.* Exploration of the plausible mechanism of ethambutol-induced ocular toxicity using proteomics-informed PBPB modeling. *Pharm Res*, 2022;39(4):677-89.
13. Kyncl M, Fus M, Lestak J. Ethambutol-induced optic neuropathy. *Biomed Pap Med Fac Univ Palacky Olomouc Czechoslov*, 2023;167(3):288-93.
14. Peterson E, Hawy E. Delayed and reversible ethambutol optic neuropathy. *Am J Ophthalmol Case Rep*, 2022;27:101611.
15. Sheng WY, Wu SQ, Su LY, Zhu LW. Ethambutol-induced optic neuropathy with rare bilateral asymmetry onset: A case report. *World J Clin Cases*, 2022;10(2):663-70.
16. Han KE, Yoon H, Choi H, *et al.* Factors affecting visual outcome in toxic optic neuropathy caused by ethambutol. *Sci Rep*, 2025;15:6257.
17. Patel J, Patel C, Shah A, Shah P, Pandya S, Sojitra B, *et al.* Ethambutol-induced optic neuritis and vision loss: A case report. *Cureus*, 2024;16(7):64873.